

Actinic Keratosis at Student-Run Free Clinic: Need for Patient Education

Caroline Zhu¹, B.S., Giselle Guerrero¹, B.S., Kavina Patel¹, B.S., Marie Vu¹, B.S.A., Jessica Wong¹, B.S., Pavela Bambekova², M.D., John Browning², M.D., M.B.A.

¹University of Texas Health Sciences Center at San Antonio School of Medicine, San Antonio, TX

²University of Texas Health Sciences Center, Department of Dermatology, San Antonio, TX

BACKGROUND

- ❖ Travis Park Dermatology Clinic is a student-run free clinic that was established in 2009 with the mission of providing free dermatological care to the uninsured and homeless populations of San Antonio.
- ❖ The clinic is held every 1st and 3rd Wednesday evening of the month and serves 20-25 patients during each clinic.
- ❖ Actinic keratoses (AK) are common, sun-induced lesions that can potentially progress to squamous cell carcinoma.
- ❖ AKs tend to recur, and patients are advised to follow-up once a year, and once every 6 months if there is a history of skin cancer.

RESULTS

- ❖ Of the 1,408 dermatology patient records during the 24-month time frame since we transitioned to our EMR system, 8 patients were diagnosed with actinic keratosis at our clinic
- ❖ 4 Female, 4 Male
- ❖ Average age: 56 years old
- ❖ Two patients had a previous diagnosis of skin cancer (unknown type)
- ❖ Three patients had a family history of skin cancer
- ❖ Average of 2.5 AK lesions per patient
- ❖ Seven of the eight patients elected to undergo treatment with cryotherapy.
- ❖ Six patients had discussions about sun protection; two patients had charted notes about explaining the need for follow-up.
- ❖ Only one patient returned to the clinic, and this individual was found to have a recurrent AK lesion that required further treatment.

CONCLUSIONS

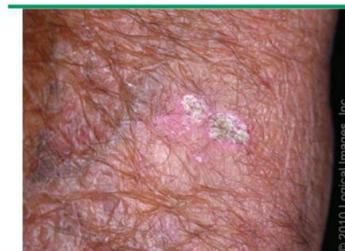- ❖ As most AK patients are advised to follow up once a year, it is crucial that our free clinic emphasize the importance of follow-up as well as sun protection
- ❖ Actinic keratoses have been found to be highly recurrent, especially in patients with multiple lesions.
- ❖ As a treatable and preventable condition, actinic keratosis is one modifiable way our clinic can make a significant impact on the community through careful communication and thorough patient education.
- ❖ To help achieve this goal, we have created a patient handout on the natural progression of AK to squamous cell carcinoma and the need for sun protection in preventing AKs.

METHODS

- ❖ To better serve our patients with actinic keratosis, we conducted a retrospective review using our RedCap electronic medical record (EMR) system to evaluate treatment and follow-up in patients with a new diagnosis of AK in our clinic.
- ❖ Patient charts were evaluated using multiple parameters such as sex, age, family history, lesion description, and follow-up.



Actinic keratosis

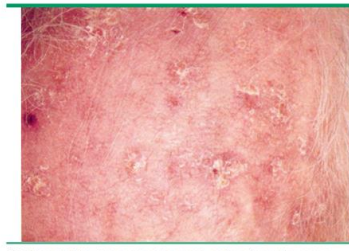


Actinic keratosis. Scale overlies erythematous macules.

Reproduced with permission from: www.visualdx.com. Copyright VisualDx. All rights reserved.

Images courtesy of 2020 UpToDate, Inc. and/or its affiliates

Actinic keratosis



Multiple actinic keratoses present as rough, scaly, red macules on sun-damaged skin.

Reproduced from: Fitzpatrick TB, Johnson RA, Wolff K, Suurmond D. Color Atlas and Synopsis of Clinical Dermatology: Common and Serious Diseases. (4th Ed). McGraw-Hill, New York 2001. p.220.

CONTACT INFORMATION

Caroline S. Zhu, B.S.


Medical Student

Long School of Medicine Class of 2022

UT Health San Antonio

✉ zhuc5@uthscsa.edu

🐦 [carolineszhu](https://twitter.com/carolineszhu)



BACKGROUND

- ❖ Travis Park Dermatology Clinic is a student-run free clinic that was established in 2009 with the mission of providing free dermatological care to the uninsured and homeless populations of San Antonio.
- ❖ The clinic is held every 1st and 3rd Wednesday evening of the month and serves 20-25 patients during each clinic.
- ❖ Actinic keratoses (AK) are common, sun-induced lesions that can potentially progress to squamous cell carcinoma.
- ❖ AKs tend to recur, and patients are advised to follow-up once a year, and once every 6 months if there is a history of skin cancer.



METHODS

- ❖ To better serve our patients with actinic keratosis, we conducted a retrospective review using our RedCap electronic medical record (EMR) system to evaluate treatment and follow-up in patients with a new diagnosis of AK in our clinic.
- ❖ Patient charts were evaluated using multiple parameters such as sex, age, family history, lesion description, and follow-up.



Travis Park

Dermatology Clinic

A STUDENT RUN FREE CLINIC

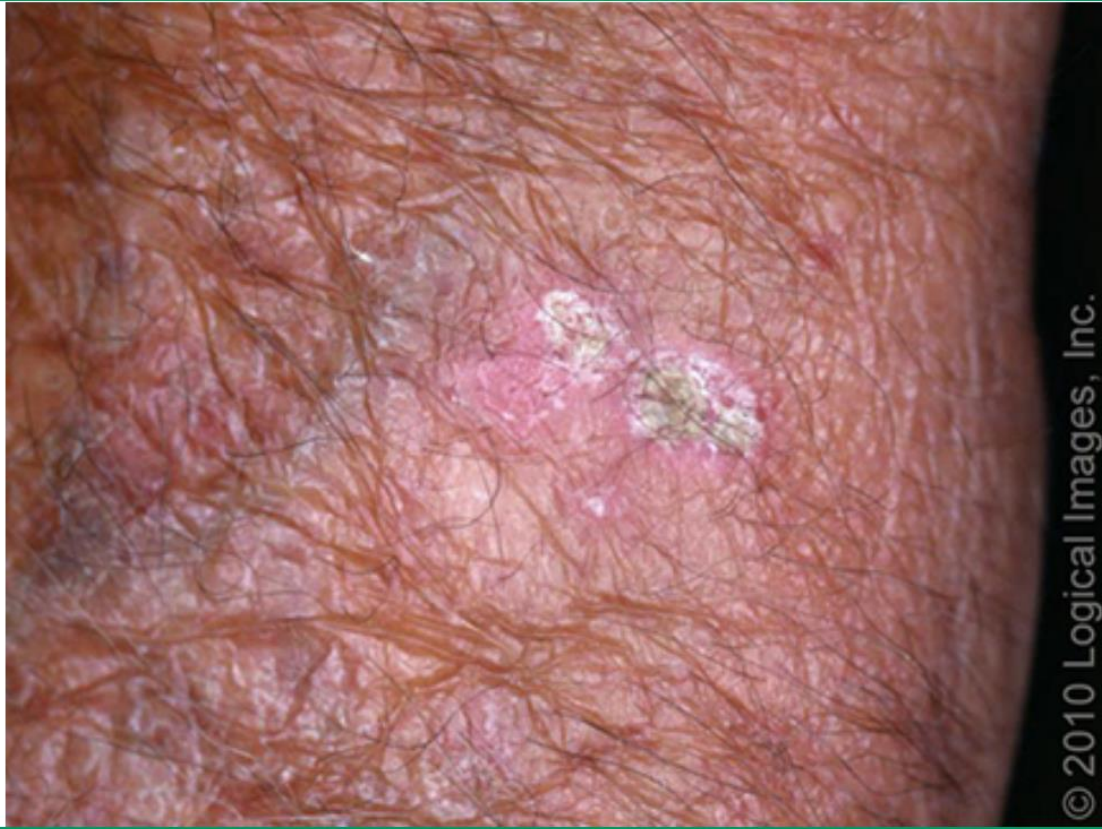

RESULTS

- ❖ Of the 1,408 dermatology patient records during the 24-month time frame since we transitioned to our EMR system, 8 patients were diagnosed with actinic keratosis at our clinic
- ❖ 4 Female, 4 Male
- ❖ Average age: 56 years old
- ❖ Two patients had a previous diagnosis of skin cancer (unknown type)
- ❖ Three patients had a family history of skin cancer
- ❖ Average of 2.5 AK lesions per patient
- ❖ Seven of the eight patients elected to undergo treatment with cryotherapy.
- ❖ Six patients had discussions about sun protection; two patients had charted notes about explaining the need for follow-up.
- ❖ Only one patient returned to the clinic, and this individual was found to have a recurrent AK lesion that required further treatment.



Actinic keratosis

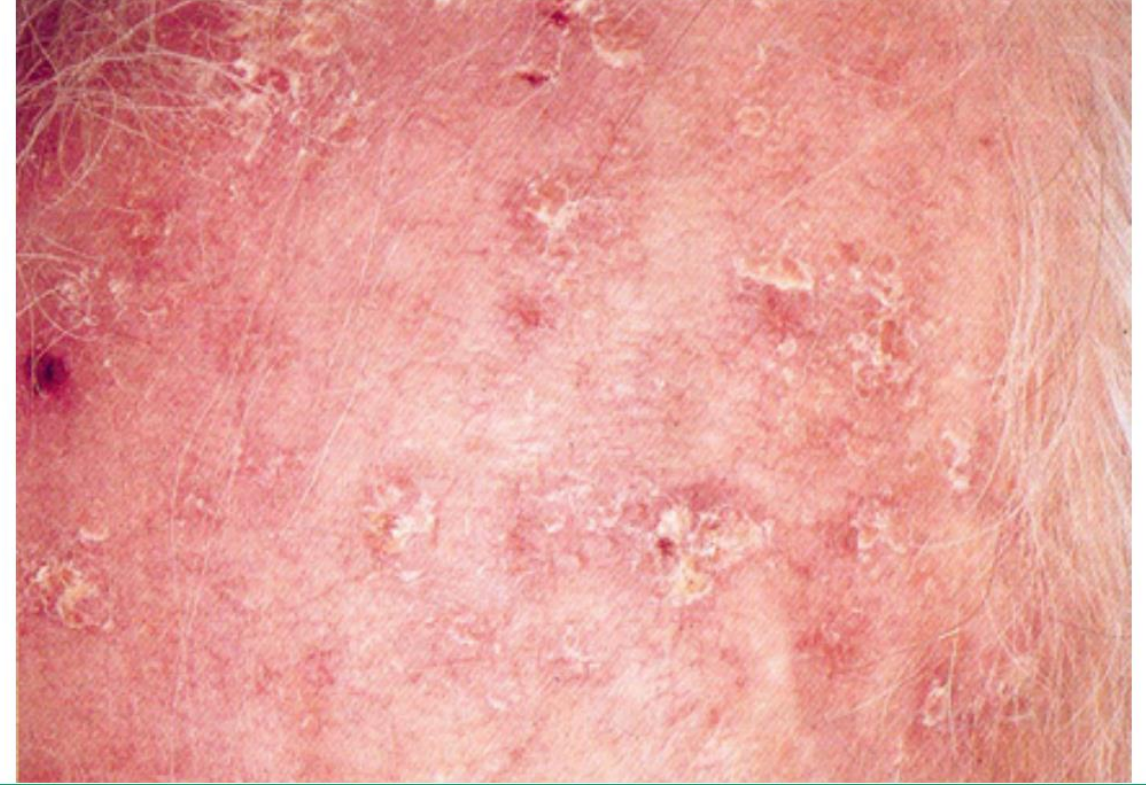


Actinic keratosis. Scale overlies erythematous macules.

Reproduced with permission from: www.visualdx.com. Copyright VisualDx. All rights reserved.

Images courtesy of 2020 UpToDate, Inc. and/or its affiliates

Actinic keratosis



Multiple actinic keratoses present as rough, scaly, red macules on sun-damaged skin.

Reproduced from: Fitzpatrick TB, Johnson RA, Wolff K, Suurmond D. *Color Atlas and Synopsis of Clinical Dermatology. Common and Serious Diseases. (4th Ed)*, McGraw-Hill, New York 2001. p.220.

CONCLUSIONS

- ❖ As most AK patients are advised to follow up once a year, it is crucial that our free clinic emphasize the importance of follow-up as well as sun protection
- ❖ Actinic keratoses have been found to be highly recurrent, especially in patients with multiple lesions.
- ❖ As a treatable and preventable condition, actinic keratosis is one modifiable way our clinic can make a significant impact on the community through careful communication and thorough patient education.
- ❖ To help achieve this goal, we have created a patient handout on the natural progression of AK to squamous cell carcinoma and the need for sun protection in preventing AKs.



CONTACT INFORMATION

Caroline S. Zhu, B.S.

Medical Student

Long School of Medicine Class of 2022

UT Health San Antonio

✉ zhuc5@uthscsa.edu

🐦 [carolineszhu](https://twitter.com/carolineszhu)

